

Managing the open abdomen using the VENTURI™ Negative Pressure Wound Therapy system

Lindsey Bullough, Tissue Viability Nurse, Wrightington, Wigan and Leigh NHS Trust
Helena Foster RGN, Group Clinical Manager, Talley Group Limited

Introduction

The intricate management of patients with an open abdomen presents both surgeons and the healthcare professionals involved in the individuals' holistic care with a challenge.

Complete closure of the abdominal fascia and abdominal wall following laparotomy subsequent to surgical exploration for abdominal trauma, operative misadventure, or relief of abdominal compartment syndrome, may be technically impossible. Instead the abdomen may need to remain open to allow access for re-operation and time for decompression of the abdomen (Kaplan et al, 2005).

In reality there is no such thing as an open abdomen post surgery. This would lead to desiccation (drying/mummification) and death of the bowel plus internal infection. All open abdomens are closed with an airtight dressing for protection.

Although numerous techniques for temporary abdominal closure have been cited in the literature, no clear consensus on the best technique or device to manage an open abdomen exists. Further studies and continued advances in this arena need to be addressed, which in turn may lead to improved comprehension of optimal treatment strategies for these devastating wounds (Kaplan et al, 2005).

Case Study

The following case study focuses on the initial achievable aims and objectives when managing an open abdomen.

In this case the patient was being cared for in the Intensive Care Unit. His general condition and prognosis were poor due to other medical complications; nevertheless, the consultant surgeon decided to manage the open abdominal wound with negative pressure wound therapy (NPWT) and requested lower pressure settings.

Therefore, the VENTURI™ NPWT system and large sealing kit from Talley Group Limited were utilised in this particular case. The kit consists of a large roll of anti-microbial dressing (AMD) gauze, a flat drain, two large transparent films, normal saline, a hydrocolloid strip and extension tubing. In addition to this the VENTURI™ gel strip was also used.

The anti-microbial agent in the AMD gauze is poly-hexamethylene biguanide (PHMB) 0.2%. PHMB exerts little toxicity and has been in use for over 60 years, with no evidence of the development of resistance (Larkin et al, 1992).

The AMD dressings have been designed as a prophylactic measure. AMD gauze containing PHMB 0.2% works by decreasing the bacterial load in the dressing and bacterial penetration through the dressing, thereby protecting the wound against potential infection (Moore & Gray, 2007).

Aims and Objectives

The initial aims and objectives when managing the open abdomen are:-

- To remove excess fluid and oedema, and document accurate drainage
- To maintain a moist healing environment
- To prevent infection
- To prevent fistula/abscess formation

Method

In this case the exposed bowel was protected with a mesh, kept insitu by sutures. As a safeguard, a non-adherent wound contact layer was placed over the mesh/bowel prior to commencing NPWT.

The large roll of AMD gauze was moistened with normal saline; a layer of moistened gauze was placed over the non-adherent wound contact layer and manipulated into all the undermined areas of the wound. The flat drain, which did not require shortening, was placed at the lower end of the wound. The remaining gauze was used to cover the drain and fluffed up to skin level.

The lower aspect of the wound had been bordered with the VENTURI™ gel strips to enhance an air tight seal once the transparent film was applied. The whole wound was covered with the transparent film, and the drainage tubing was connected to the canister. Since the surgeon had requested the use of lower pressures, therapy was initiated at 60mmHg (Chariker, Jeter et al, 1989).

Managing the open abdomen using the VENTURI™ Negative Pressure Wound Therapy system

Results

Day 1: The wound measurements on day one were as follows:- 26cm length x 23cm width. Within the first sixteen hours of commencing NPWT, one litre of serous fluid had been drained into the canister. After forty-eight hours the surgeon reviewed the wound on the first dressing change; although there was no significant difference noted to the wound, despite copious amounts of drainage, the surgeon was happy with the dressing application and the use of lower pressures. NPWT continued.

Day 5: Fig. 1 shows the wound at the second dressing review. The exposed bowel appeared less oedematous and the sloughy areas appeared to be loosening. Three litres of fluid had been drained from the wound in five days.

Day 8: On day eight the multi-disciplinary team were concerned that an infection may be present in the wound. NPWT was ceased but resumed on day nine.

Day 11: Fig. 2 shows the dressing insitu, prior to the dressing change on day eleven. Fig. 3 shows the wound at eleven days. It is evident that the wound edges appear healthier, the slough is loosening and the bowel is not as swollen.

Unfortunately on day 12, due to other medical complications, the patient died.

Discussion

Whilst this wound was being managed with the VENTURI™ NPWT system, the multi-disciplinary

team found the dressing application easy and straightforward. The ability to manipulate the moistened gauze to the undermined areas minimised the possibility of abscess formation. The use of lower pressure settings enabled sufficient fluid drainage whilst reducing the risk of fistula formation. Accurate drainage was documented as the fluid was easily measurable in the canister. Overall the initial aims and objectives set were achieved.

Conclusion

Although the management of the open abdomen still presents as a challenge for the multi-disciplinary team, the VENTURI™ NPWT system provides another alternative to consider when further studies are undertaken to fully understand this surgical dilemma.

References

Chariker, M.E., Jeter, K.F., Tintle, T.E., Bottsford, J.E. (1989) *Effective management of incisional and cutaneous fistulae with closed suction drainage*. Contemporary Surgery Vol. 34, 59-63.

Kaplan, M., Banwell, P., Orgill, D., Ivatury, R., Demitriades, D., Moore, F., Miller, P., Nicholes, J., Henry, S. (2005) *Guidelines for the management of the open abdomen*. Supplement to Wounds: A Compendium of Clinical Research and Practice.

Larkin, D.F., Kilvington, S., Dart, J.K. (1992) *Treatment of Acanthamoeba keratitis with polyhexamethylene biguanide*. Ophthalmol, 99(2), 185-91.

Moore, K., Gray, D. (2007) *Using PHMB antimicrobial to prevent wound infection*. Wounds UK, Vol. 3, No. 2, 96-102.

Talley Medical would like to thank Lindsey Bullough for undertaking this study, together with the patient and his family for allowing us to publish the study.

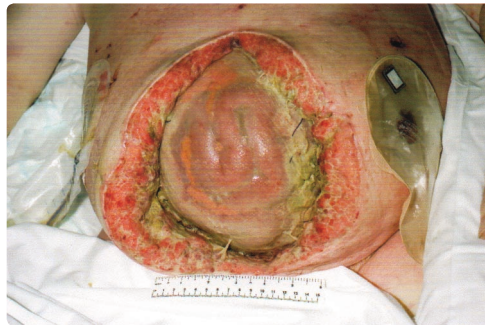


Fig. 1 (DAY 5)

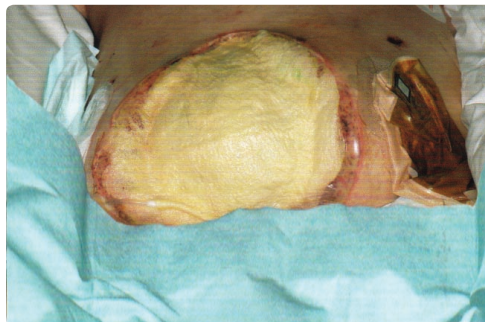


Fig. 2 (DAY 11)

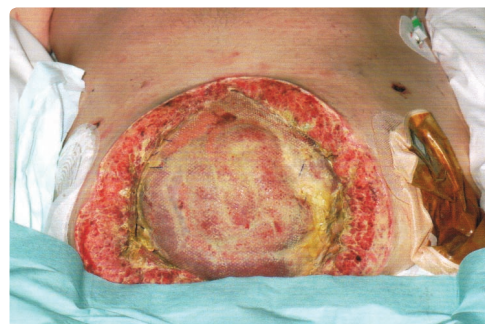

Fig. 3 (DAY 11)

Talley Medical products are manufactured to comply with BSI, IEC, UL and other European safety standards. Talley Medical design and manufacture products to conform to the requirements of ISO9001:2000, ISO13485:2003 and Directive (93/42/EEC) Annex II (excluding Section 4). Every care has been taken to ensure that the information contained in this brochure was correct at the time of going to press. However, Talley Medical reserves the right to modify the specification of any product without prior notice in line with a policy of continual product development. Our standard terms and conditions apply. © Talley Group Limited 2008. All rights reserved.