

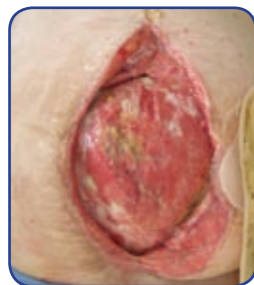Case Study 3 Results (continued)

x 13cm with the wound bed beginning to show signs of granulation and no signs of infection.

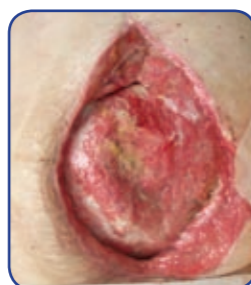Day 5: The wound bed had continued to granulate, and the dimensions remained the same. At this point the patient was reviewed by a surgical team with a view to grafting the area. It was felt appropriate to continue with the NPWT pump for a further five days until surgery.

Day 10: In this final review it can be seen that the wound bed continued to develop granulation tissue and was free from infection. It was considered appropriate to proceed with a skin graft to the area so NPWT was discontinued.

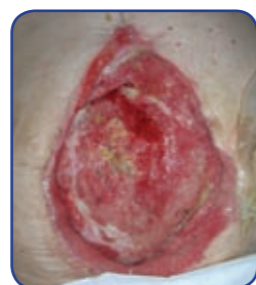The results obtained in this study enabled this gentleman to return to theatre for grafting of the abdominal wound.



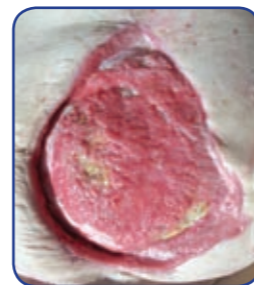Day 1



Day 3



Day 5



Day 10

Discussion

In all cases the NPWT system was easy to operate and maintain. In these three cases, which form part of a larger ongoing cohort of studies, the NPWT system has proved straightforward and effective with no complications observed. The use of gauze as the interface did not result in adherence to the wound bed, a concern of the clinicians prior to use.

Conclusion

In all three case studies the results obtained were beneficial and clinically effective, and the aims outlined were achieved. The case studies are evidence that a NPWT system incorporating moistened gauze and a silicone drain

is an effective alternative method of manipulating the wound environment in order to promote healing. Therefore, when assessing wounds that may clinically benefit from the use of negative pressure wound therapy, this type of NPWT system is worth contemplating.

References

1. *The Kremlin Papers: A collection of published studies complementing the research and innovation of wound care.* Vestnik Khirurgii 1986-1991
2. Chariker, M.E., Jeter, K.F., Tintle, T.E., Bottsford, J.E. (1989) *Effective management of incisional and cutaneous fistulae with closed suction drainage.* Contemporary Surgery Vol. 34, 59-63.

Talley Medical would like to thank Fiona Russell (TVN), David Gray (CNS), Pam Cooper (CNS), John Timmons (TVN) and Sandra Stringfellow (TVN) of the Department of Tissue Viability, Grampian Health Services, Aberdeen for undertaking these case studies.

Three Clinical Evaluations of Negative Pressure Wound Therapy Utilising Moistened Gauze and a Silicone Drain

Helena Foster RGN - Group Clinical Manager, Talley Group Limited

Introduction

Treating wounds with Negative Pressure Wound Therapy (NPWT) is not a new concept. The use of negative pressure in wounds began in the modern era with Raffel in 1952. The Russians have extensively used vacuum to assist with healing wounds for many years. The Kremlin papers, a series of five articles published in the Russian medical literature from 1986-1991 document their results¹.

Until recently the only interface through which negative pressure was applied was via polyurethane foam; however with the emergence of alternative therapies the interface used to compliment these therapies is moistened gauze and a silicone drain, which provides an alternative method of manipulating the wound environment in order to promote healing.

The clinical benefits obtained by using topical negative pressure wound therapy include:-

- Removal of excess fluid and oedema
- Assistance with wound contraction
- Stimulation of granulation tissue
- Protection from outside contaminants
- Increase in Vascular perfusion
- Decrease in wound bioburden
- Remodelling of connective matrix
- Encouragement of maturation of epithelial cells
- Maintaining a moist healing environment

The following clinical evaluations highlight the clinical benefits and effectiveness of a NPWT system which utilises moistened gauze, a silicone drain and transparent film in order to achieve the clinical outcome required.

Depending on the type of wound being treated, there are a choice of drains. A flat drain is suitable for moderate depth wounds with moderate drainage, and a channel drain is used for sinus management and undermining. A flat drain was utilised in each of the featured case studies.

• **CASE STUDY 1**

A 38 year old man with pressure damage to his left heel. In this case the aim of NPWT was to develop sufficient granulation for the patient to be discharged and managed in the community.

• **CASE STUDY 2**

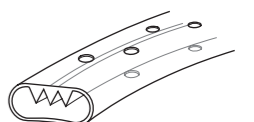
Male patient who presented with a 4cm x 2.1cm dehiscd sternotomy wound post cardiac surgery. In this case, the aim of NPWT was to deslough and speed the healing of a dehiscd surgical wound over a 15 day period.

• **CASE STUDY 3**

A 58 year old man who had undergone a laparotomy procedure and the resultant wound had dehiscd. In this case NPWT was used over a ten day period to prepare the patient for skin grafting by developing a granulating wound bed.

Method

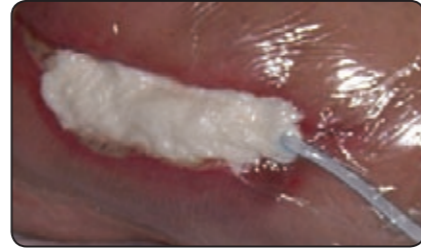In all three case studies the wound was irrigated with normal saline and the surrounding skin patted dry. A layer of moistened gauze was placed directly on the wound bed. The flat drain was then cut to size and placed on top of the gauze, approximately 1-2cm from the wound edges to allow for contraction.



Flat drain

The drain was then covered by the remaining moistened gauze and fluffed up to skin level. The entire wound was covered with transparent film. By applying a transparent dressing with an adequate seal a moist environment is maintained. Hence the gauze is moist

to moist, not wet to dry. The flat drain was then connected to a NPWT pump unit and the pressure was initially set at 80mmHg of continuous negative pressure². Canister changes took place weekly or whenever it was felt necessary.



Example of sealed wound using moistened gauze and a silicone drain

Case Study 1 Results

This 38 year old man was admitted for rehabilitation following fracture of his right tibia and fibula sustained during a fall from his wheelchair which he requires due to spina bifida.

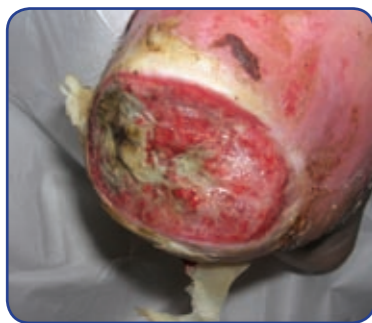He sustained bilateral pressure ulcers with the most severe occurring on his left heel. On first review this wound measured 6cm x 5cm and was covered with black/yellow slough which was removed using a combination of larvae therapy and conservative sharp debridement.

Day 1: Following debridement this patient was commenced on a NPWT pump set at 80mmHg. At this point the wound was covered with approximately 25% sloughy and 75% granulation tissue with no evidence of clinical infection. In the centre of the wound the depth of the wound was 0.5cm.

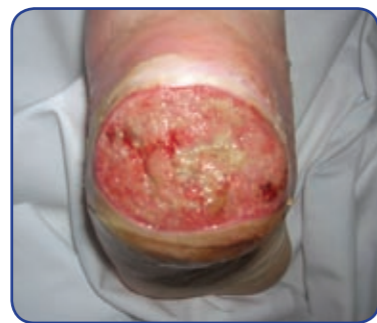Day 7: At this review the wound dimensions were of day 1 with the exception of the depth of the wound which was 0cm. There was no evidence of infection and the wound bed appeared 100% granulation with superficial areas of slough on the surface.

Day 14: The wound showed no signs of infection and the granulation had begun to flatten with a small amount of epithelialisation at the wound margins. At this stage the wound had improved sufficiently over the previous 14 days for the patient to be discharged on conventional wound management products and managed in the community.

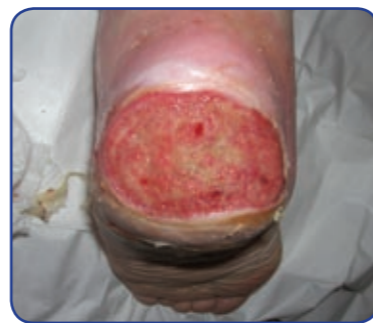In this particular case, the dressing changes were relatively easy, in what may be considered an awkward area. The dressings remained intact between dressing changes without any leaks or drops in pressure.



Day 1



Day 7



Day 14

Case Study 2 Results

This man presented with a 4cm x 2.1cm dehiscd sternotomy wound post cardiac surgery. The wound was covered with slough and treated with larvae therapy for a week prior to being commenced on a NPWT pump.

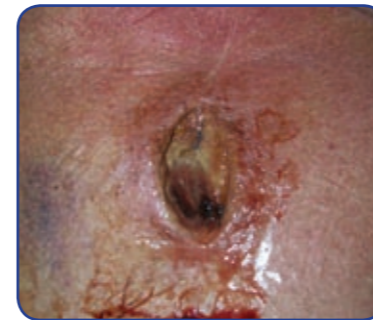Day 1: The wound dimensions remained at 4cm x 2.1cm and the wound bed remained covered in slough although decreased following larval therapy. There was no evidence of wound infection. A NPWT pump was commenced at 80mmHg on continuous suction.

Day 7: The wound dimensions had reduced to 4cm x 1.7cm with no evidence of infection and a granulating wound bed and wound margins with some superficial

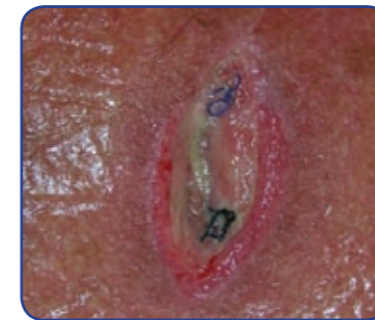slough on the wound bed.

Day 15: The wound dimension was now 1.5cm x 1.3cm and there was evidence of epithelialisation and contraction at the wound margins, with no signs of infection. At this point the patient was discontinued from the NPWT pump and transferred onto a hydrocolloid so as to facilitate his mobilisation and subsequent discharge.

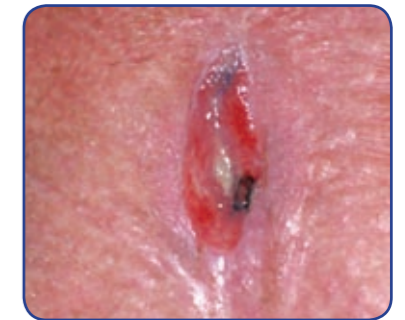Use of a NPWT system in this particular case proved to be extremely beneficial to this patient, who had a six week history of dehiscence with a 100% covering of slough on the wound bed. Dressing changes took place every 48 hours.



Day 1



Day 7



Day 15

Case Study 3 Results

In this case the patient was a 58 year old man who had undergone a laparotomy procedure and the resultant wound had dehiscd.

Day 1: At first review the wound measured 19cm x 10.5cm and the wound was malodorous, producing high

volumes of medium viscosity exudate. The wound bed was granular with superficial slough in patches with some evidence of fat necrosis. A NPWT pump was set at 80mmHg on continuous suction.

Day 3: The wound dimensions had enlarged to 20cm